



Surgical Considerations and Decision Making in SFOT/PAOO

Journal:	<i>Clinical Advances in Periodontics</i>
Manuscript ID	Draft
Manuscript Type:	Practical Applications
Date Submitted by the Author:	n/a
Complete List of Authors:	Kao, Richard;
Abstract:	<p>Abstract</p> <p>Background: Surgically facilitated orthodontic treatment (SFOT)/ periodontally accelerated osteogenic orthodontics (PAOO) has the potential of allowing safer orthodontic treatment in vulnerable periodontiums with thin phenotypes. SFOT/PAOO is a phenotype modification therapy (PhMT) approach where thin bone morphotype and/or gingiva are surgically augmented to convert a fragile-thin to a robust-thick periodontal environment. This permits orthodontic treatment in these previously thin phenotype cases to proceed without iatrogenically-induced adverse effects.</p> <p>Methods: In this practical application paper, three clinicians with the collective clinical experience of over 1,500 SFOT cases developed a clinical decision-making algorithm outlining the key steps for SFOT. A sample case is provided for clinical appreciation of the procedure.</p> <p>Lastly, this panel reviewed and detailed the critical decision making and surgical approaches associated with the use of SFOT.</p> <p>Results: Though the basic decision making is consistent, individual variations on surgical management are compared. This is summarized in a clinical decision tree along with a sample clinical case. Additionally, the cumulative experience has been organized into tables that provide comparative decision and surgical approaches. There are similarities and differences. Lastly, strategies that have not been individually effective are also noted.</p> <p>Conclusion: SFOT/PAOO is an effective PhMT approach whereby the bone and/or soft tissue phenotype can be surgically modified to permit orthodontic treatment in patients with thin phenotypes.</p>



CAP Paper #4: Surgical consideration of SFOT/PAOO

Surgical Considerations and Decision Making in SFOT/PAOO

Mandelaris, George A.^{1,2,3}, Richman, Colin³, Kao, Richard T^{4,5}

1. Periodontics and Oral Medicine, University of Michigan, Ann Arbor, MI
2. Graduate Periodontics, University of Illinois, Chicago, IL
3. Private practice, Chicago, IL
4. Private practice, Atlanta, GA
5. Orofacial Sciences, University of California San Francisco, San Francisco, CA
6. Private practice, Cupertino, CA

CAP Paper Type: Practical Applications to be part of BEC Series on modifying gingival phenotype in preparation for orthodontic treatment

Communicating author: Richard T. Kao, DDS, Ph.D.
richkao@sbcglobal.net

Word Count: 1,990 (text) =215 (abstract)

Running Title: Consensus recommendations for SFOT

Key Words: gingival thickness; orthodontics; guided tissue regeneration; tissue engineering; risk factor(s)

Key Findings: Surgically facilitated orthodontic treatment (SFOT), also known as periodontally accelerated osteogenic orthodontics (PAOO), has the objective of augmenting the hard and soft tissue components of a thin periodontal phenotype patient such that orthodontic treatment has expanded opportunities for tooth movement and better overall treatment outcomes.

CAP Paper #4: Surgical consideration of SFOT/PAOO

Abstract

Background: Surgically facilitated orthodontic treatment (SFOT)/ periodontally accelerated osteogenic orthodontics (PAOO) has the potential of allowing safer orthodontic treatment in vulnerable periodontiums with thin phenotypes. SFOT/PAOO is a phenotype modification therapy (PhMT) approach where thin bone morphotype and/or gingiva are surgically augmented to convert a fragile-thin to a robust-thick periodontal environment. This permits orthodontic treatment in these previously thin phenotype cases to proceed without iatrogenically-induced adverse effects.

Methods: In this practical application paper, three clinicians with the collective clinical experience of over 1,500 SFOT cases developed a clinical decision-making algorithm outlining the key steps for SFOT. A sample case is provided for clinical appreciation of the procedure. Lastly, this panel reviewed and detailed the critical decision making and surgical approaches associated with the use of SFOT.

Results: Though the basic decision making is consistent, individual variations on surgical management are compared. This is summarized in a clinical decision tree along with a sample clinical case. Additionally, the cumulative experience has been organized into tables that provide comparative decision and surgical approaches. There are similarities and differences. Lastly, strategies that have not been individually effective are also noted.

Conclusion: SFOT/PAOO is an effective PhMT approach whereby the bone and/or soft tissue phenotype can be surgically modified to permit orthodontic treatment in patients with thin phenotypes.

CAP Paper #4: Surgical consideration of SFOT/PAOO

Background

Orthodontic treatment is limited by the inherent regional hard and soft tissue anatomy within any individual. This BEC paper focuses on surgical phenotype modification therapy (PhMT) in concert with orthodontic treatment. While the modification of soft tissue through various augmentative procedures has been extensively detailed at the 2014 Regeneration Workshop,^{1,2} orthodontic treatment may require bone augmentation of the osseous housing and, at times, increasing the gingival tissue thickness. This is necessary such that orthodontic tooth movement does not result in increased development of bony dehiscence and fenestration and potential gingival recession, mobility, and create risk for future recession-based attachment loss.

Surgically facilitated orthodontic therapy (SFOT) is a surgical procedure which can permit the pursuit and completion of more complicated orthodontic cases in an area with minimal or inadequate soft and hard tissue volume.³⁻⁵ SFOT describes a broad category of surgical procedures that can facilitate and support orthodontic therapy. This would include the use of corticotomy surgery plus dentoalveolar bone decortication with bone augmentation +/- gingival grafting which has been popularized as periodontally accelerated osteogenic orthodontics (PAOO). As a broader category, SFOT also includes the use of temporary anchorage device (TAD) and/or anchor plates. The term PAOO has been described by others under the patented name of accelerated osteogenic orthodontics (AOO) or Wilcodontics.TM In this paper, SFOT will focus on the use of dento-alveolar corticotomy surgery with dentoalveolar bone decortication and bone augmentation to facilitate orthodontic treatment +/- soft tissue grafting.³ This procedure is efficacious in the treatment of malocclusion by increasing alveolar volume and enhancing

CAP Paper #4: Surgical consideration of SFOT/PAOO

1
2
3
4 periodontal phenotypes.³ It is also efficacious in the management of dentoalveolar deficiencies
5
6 that when tooth movement exceeds the orthodontic boundary conditions. The benefits of SFOT
7
8 include accelerated treatment time,⁶ greater stability of clinical outcome with less relapse,⁷ and
9
10 enhanced the scope of treatment for malocclusion.³ Clinically, SFOT has been shown to resolve
11
12 crowding of the natural dentition⁴, facilitate eruption of impacted teeth,⁸ accelerate canine
13
14 retraction,⁴ intrusion and open bite correction,^{3,8} and facilitate borderline
15
16 orthognathic/orthodontic surgical cases.⁹ Stability post-orthodontically is also a key benefit, in
17
18 that there is less post-orthodontic relapse observed.¹⁰ With bone augmentation that is performed
19
20 in conjunction with the corticotomy surgery, the increased thickness of the alveolar bone is
21
22 believed to enhance post-orthodontic stability of the dentition.¹¹ In a 2016 systematic review,⁶
23
24 corticotomy did not result in negatively influencing periodontal health, including periodontal
25
26 probing depth, gingival recession, clinical attachment levels and alveolar crestal bone heights.
27
28
29
30
31
32

33
34 While the treatment planning of these cases is complicated, as described in the previous paper,¹²
35
36 the surgical operational aspect of the procedure is familiar and highly suited to periodontists with
37
38 advanced training in this therapeutic modality. In this paper, three experienced clinicians with at
39
40 least over 1,500 collective cases have developed a decision tree for SFOT, and shared their
41
42 surgical experiences and various management approaches. It is the objective of this BEC series
43
44 to have the profession develop a familiarity, level of comfort, and an appreciation for the
45
46 treatment in managing this type of interdisciplinary treatment requiring SFOT.
47
48
49
50
51

52 **Decision Process**

53
54
55
56
57
58
59
60

CAP Paper #4: Surgical consideration of SFOT/PAOO

1
2
3
4 In the orthodontic management of thin phenotype cases, the critical decision is to determine if
5
6 the periodontal phenotype has adequate soft tissue (keratinized tissue width and gingival
7
8 thickness) with a bone morphotype that will be conducive to the planned tooth movement. If
9
10 not, the periodontium can be modified by SFOT either with bone augmentation or as a separate
11
12 procedure prior to corticotomy and bone augmentation, a subcategory of PhMT strategies.
13
14 Depending on the extent of the thin soft tissue morphology (keratinized tissue width, gingival
15
16 thickness, and the presence /risk for gingival recession), the soft tissue augmentation may be
17
18 performed simultaneously with corticotomy surgery and bone augmentation or can be addressed
19
20 as a preliminary preparatory surgical procedure. In this latter situation, an additional 3 months of
21
22 healing is required. In Fig. 1, the panel jointly developed a decision tree for SFOT with or
23
24 without soft tissue augmentation. Additionally, the panelists compared and contrasted their
25
26 various approaches to SFOT.
27
28
29
30
31
32

Clinical Scenarios

33
34
35
36 In the treatment of thin phenotype cases requiring tooth movement, orthodontic treatment may
37
38 require SFOT. Should the overlying gingival tissue be suspected to be inadequate to support the
39
40 bone augmentation, PhMT may require surgical correction or embellishment of the mucogingival
41
42 tissue. This often involves soft tissue augmentation using autogenous or tissue substitute
43
44 materials. If localized, this may be addressed during the corticotomy-bone augmentation phase
45
46 of SFOT. If the gingival tissue is thin in a generalized fashion, preliminary soft tissue
47
48 augmentation/embellishment may be beneficial (Fig. 1).
49
50
51
52
53
54
55
56
57
58
59
60

CAP Paper #4: Surgical consideration of SFOT/PAOO

1
2
3
4 Critical stages for the management of PhMT in thin phenotype cases involve an interdisciplinary
5
6 assessment of the osseous and mucogingival tissue, the scope of proposed orthodontic tooth
7
8 movement, the actual corticotomy-bone augmentation procedure, and post-operative care. The
9
10 critical steps of SFOT are detailed in Fig 2. There are many commonalities in the therapeutic
11
12 approaches by each panelist, however there are individual preferences especially in terms of
13
14 surgical supplies as noted in Table 1-3. As noted, there are many commonalities in the
15
16 management strategies, but the surgical approaches and armamentarium may vary based on
17
18 individual preferences. The extensive experience of the group has also identified strategies that
19
20 may improve, along with those that do not enhance clinical outcomes. Once the soft tissue has
21
22 been determined to be adequate to support the corticotomy-bone augmentation phase, several
23
24 critical steps have been defined for successful outcomes. Common soft tissue deficiencies
25
26 include hyperactive frena in the mandibular anterior segments or bicuspid teeth of one or both
27
28 arches, resulting in a deficiency of attached and keratinized gingival tissues. A clinical case is
29
30 provided to define these steps (see Fig 2 for clinical case). Though there are subtle differences
31
32 between the three clinicians.
33
34
35
36
37
38
39

Discussion

40
41
42 Orthodontic treatment limitation is usually based on the extent of the proposed orthodontic tooth
43
44 movement and osseous boundaries as defined by the CBCT analysis¹²⁻¹⁴ (Mandelaris, 1st BEC,
45
46 Mandelaris, 2020). The extent of tooth movement is somewhat subjective and variable as the
47
48 modulus of elasticity of dentoalveolar bone (in vivo and in humans) has no consensus. Proffit's
49
50 envelope of discrepancy can be cited for some direction on malocclusion case management, but
51
52 these numbers do not consider opportunities when dentoalveolar bone augmentation has been
53
54
55
56
57
58
59
60

CAP Paper #4: Surgical consideration of SFOT/PAOO

1
2
3
4 performed.¹⁵ Ferguson et al published on the scope of treatment with periodontally accelerated
5
6 osteogenic orthodontic therapy and reported that certain tooth movements can be 2x to 3x greater
7
8 that of conventional orthodontic parameters, from a horizontal (bucco-lingual) or vertical.³ The
9
10 extent of tooth movement and need for dentoalveolar bone augmentation is best evaluated with
11
12 3D simulation technology that allows the dentoalveolar bone complex to be scrutinized as to the
13
14 influence on those structures from tooth movement.¹² Displaying only the crowns of teeth in
15
16 software simulations (whether for traditional orthodontic appliances or for aligner therapy) does
17
18 not respect the periodontium attached to the crowns of teeth and does not provide transparency to
19
20 unavoidable changes that occur within the dentoalveolar bone complex when tooth movement
21
22 occurs. It is the periodontist's responsibility to define areas where hard and/or soft tissue
23
24 augmentation will be needed and how much augmentation is possible to enhance dentoalveolar
25
26 bone volume to which arch forms can be decompensated or corrected This starts, in part, with an
27
28 analysis of the mucogingival status with focus on the keratinized tissue width, gingival thickness,
29
30 and presence/risk for recession^{16,17} after confirming a healthy oral situation relative to gingivitis
31
32 or periodontitis, localized or generalized. Marginal tissue may be defined as thick vs. thin. This
33
34 group found that the most convenient approach is to use the phenotype probe visibility test. (Hu
35
36 Friedy). It is important to define if the areas of soft tissue deficiencies are localized or
37
38 generalized. Limited localized areas can be managed during the corticotomy-bone augmentation
39
40 procedure. If there is generalized thin soft tissue, there should be concern about whether the thin
41
42 tissue can sustain the bone augmentation procedure; in which case, it is the general consensus
43
44 that a two-step approach would be prudent. In this scenario, the panel varies on the type of
45
46 grafting to be used, but the consensus is to thicken the gingival tissue and allow for 3-4 months
47
48 of healing and revascularization. Seems repeated
49
50
51
52
53
54
55
56
57
58
59
60

CAP Paper #4: Surgical consideration of SFOT/PAOO

1
2
3
4
5
6 The corticotomy-bone augmentation procedure is the critical part of this PhMT surgery.
7
8 Interdental corticotomy and decortication of the alveolar housing creates a transient
9
10 demineralization phase within the dentoalveolar complex, and the resulting soft tissue-bone
11
12 matrix permits an accelerated rate of tooth movement due to an altered physiologic response
13
14 known as the regional acceleratory phenomenon (RAP) effect.^{7,18,19} This injury results in
15
16 acceleration of all processes involved in healing, including remodeling, cell turnover,
17
18 metabolism and repair. In individuals with thin bone morphotype, the movement of the teeth
19
20 frequently results in bone loss (fenestrations, dehiscence's) and future gingival recession. By
21
22 combining soft tissue augmentation and bone grafting techniques, it is possible to convert a thin
23
24 to a thick gingival phenotype and bone morphotype. The interdental corticotomy is performed
25
26 primarily at interdental sites, with burs or piezo surgical incision to a depth of at least 2mm.
27
28 The critical event is to extend the corticotomies beyond the cortical bone and into the medullary
29
30 area. To date, devitalization of the tooth and damage to the root structures was reported in only
31
32 one case by one panel member The corticotomies and bone augmentation should be provided on
33
34 the facial bone in the same direction of the tooth movement, that is on the pressure side For
35
36 example, if arch expansion is undertaken, the treatment is provided for the facial alveolar bone
37
38 only. Contrary to previous reports, the corticotomy-dentoalveolar bone decortication need not be
39
40 done on both buccal and lingual sides .as it has been shown that the tension side of orthodontic
41
42 tooth movement will response with bone deposition through the process of distraction However,
43
44 it should also be understood that injury to both sides may be required to achieve the desired tooth
45
46 movement as McBride et al has shown, the greater the surgical insult around the tooth, the
47
48 greater the magnitude of the RAP produced.²⁰ Though each panelist has a preferred bone graft
49
50
51
52
53
54
55
56
57
58
59
60

CAP Paper #4: Surgical consideration of SFOT/PAOO

1
2
3
4 material protocol, all panelists believe in a collagen barrier- not necessarily for guided tissue
5
6 regeneration purposes but for graft containment. The importance of flap closure and wound
7
8 stability is emphasized and all believe in the use of long termed stabilization through the use of
9
10 passive suturing.
11
12
13
14

15 Surgical healing is consistent with most regenerative and mucogingival grafting surgery.
16
17 Infection is generally rare with the main adverse event consisting of incomplete root coverage.
18
19 In extensive grafting with thin tissue thickness, superficial sloughing of the epithelium may be
20
21 observed for the first few months, which requires monitoring but no immediate active
22
23 management. Relapse of gingival recession, infrequently noted, is remedied with subsequent
24
25 corrective mucogingival surgery such as additional subepithelial connective tissue grafts or
26
27 augmentation with allograft substitute. The primary concern post-operatively is to activate
28
29 orthodontic forces after 1-10 days post-SFOT surgery. The arch wire should be activated within
30
31 the first two weeks and usually changed every other week.
32
33
34
35

36 Post-SFOT monitoring, both short term and long term include monitoring of the pocket depth,
37
38 relapse of gingival recession, soft tissue thickness, increased appearance of bone thickness from
39
40 CBCT views, obtained 1 or more years post treatment. As with any therapeutic approach,
41
42 stability of long-termed outcome is important (Fig 3).
43
44
45
46

Conclusion

47
48
49 SFOT is a PhMT that can open orthodontic treatment opportunities for a certain population of
50
51 patients with malocclusion. The corticotomy-bone augmentation procedures are inherent to our
52
53 periodontal training, but to master the use of SFOT in orthodontic treatment, an interdisciplinary
54
55
56
57
58
59
60

CAP Paper #4: Surgical consideration of SFOT/PAOO

1
2
3
4 team is essential to properly coordinate treatment sequencing, timing, surgical protocols and
5
6 address the core problems of the patient. In this context, the IDT team uses the unique individual
7
8 skillsets from each member on the team who is best suited and trained to manage each particular
9
10 piece of the puzzle for the benefit of the patient. A decision tree has been proposed and
11
12 developed from the experience of our panelist and is presented for the periodontal community's
13
14 consideration.
15
16
17
18
19
20
21
22
23
24
25
26
27
28
29
30
31
32
33
34
35
36
37
38
39
40
41
42
43
44
45
46
47
48
49
50
51
52
53
54
55
56
57
58
59
60

For Peer Review

CAP Paper #4: Surgical consideration of SFOT/PAOO

References (* indicate key references)

1. Chambrone L, Tatakis DN. Periodontal soft tissue root coverage procedures: A systematic review from the AAP regeneration workshop. *J Periodontol* 2015; 86(Suppl 2):S8-S51.
2. Kim DM, Neiva R. Periodontal soft tissue non-root coverage procedures: A systematic review from the AAP regeneration workshop. *J Periodontol* 2015;86(Suppl 2):S56-S72.
3. Ferguson DJ, Wilcko MT, Wilcko WM, Makki L Scope of treatment with periodontally accelerated osteogenics orthodontic therapy. *Seminars in Orthodontics* 2015;21:176-186.
4. * Hoogeveen EJ, Jansma J, Ren Y. Surgically facilitated orthodontic treatment: A systematic review. *Am J Orthod Dentofacial Orthop* 2014:S51-64.
5. * Wilcko MT, Ferguson DJ, Makki L, Wilcko W Keratinized Gingiva height increases after alveolar corticotomy and augmentation bone grafting *J Periodontol* 2015;86 :1107-1115.
6. Mandelaris GA, DeGroot BS, Relle R, et al. Surgically facilitated orthodontic therapy: Optimizing dentoalveolar bone and space appropriation for facially prioritized interdisciplinary dentofacial therapy. *Compendium* 2018;30:146-156.
7. Wilcko MT, Wilcko WM, Bissada NF An evidence-based analysis of periodontally accelerated orthodontic and osteogenic techniques: a synthesis of scientific perspectives. *Semin Orthod* 2008;14:305-16.

CAP Paper #4: Surgical consideration of SFOT/PAOO

- 1
2
3
4 8. Makki L, Ferguson DJ Stability of Mandibular Irregularity Index with and without
5
6 PAOO: A Review. *Adv Dent & Oral Health* 2017;4:1-3.
7
- 8 9. Akay MC, Aras A, Gunbay T, Akyalcin S, Koyuncue BO Enhanced effect of combined
9
10 treatment with corticotomy and skeletal anchorage in open bite correction. *J Oral*
11
12 *Maxillofac Surg* 2009; 67:563-9.
13
- 14
15 10. Vercellotti T, Podesta A Orthodontic microsurgery: a new surgically guided technique for
16
17 dental movement. *Int J Periodontics Restorative Dent* 2007;27:325-31.
18
- 19
20 11. Frost HM: The biology of fracture healing. An overview for clinicians Part II. *Clin*
21
22 *Orthop Relat Res* 1989;248:294-309.
23
- 24
25 12. Frost HM: The biology of fracture healing. An overview for clinicians. Part I. *Clin*
26
27 *Orthop Relat Res* 1989;248:283-293.
28
- 29
30 13. * Mandelaris et al. CAP (previous paper in CAP)
- 31
32 14. Mandelaris GA, Scheyer ET, Evans M, Kim D, McAllister B, Nevins M, Rios H,
33
34 Sarment D. American Academy of Periodontology's Best Evidence Consensus Statement
35
36 on Selected Oral Applications for Cone-Beam Computed Tomography. *J Periodontol*
37
38 2017; 88(10): 939-945
39
- 40
41 15. * Mandelaris GA, Neiva R, Chambrone L. American Academy of Periodontology Best
42
43 Evidence Consensus on Cone Beam Computed Tomography and Interdisciplinary
44
45 Dentofacial Therapy. A Systematic Review Focusing On Risk Assessment of the
46
47 Dentoalveolar Bone Changes Influenced By Tooth Movement. *J Periodontol* 2017;
48
49 88(10): 960-977
50
- 51
52 16. Proffit WR. Contemporary Orthodontics. 4th Edition, Mosby, St Louis 2007; 107-129 and
53
54 689-691.
55
56
57
58
59
60

CAP Paper #4: Surgical consideration of SFOT/PAOO

- 1
2
3
4 17. Kim D, Bassit H, Nguyen T. Effect of gingival phenotype on the maintenance of
5
6 periodontal health: An American Academy of Periodontology Best Evidence Review.
7
8 *Accepted to Journal of Periodontology.*
9
- 10
11 18. Wang C-W, Yu S-H, Mandelaris GA, Wang H-L. Is phenotypic conversion therapy
12
13 beneficial for patients receiving orthodontic treatment? An American Academy of
14
15 Periodontology Best Evidence Review. *Accepted to Journal of Periodontology*
16
- 17
18 19. Ferguson DJ, Machado I, Wilcko MT, Wilcko W Root resorption following periodontally
19
20 accelerated osteogenic orthodontics. *APOS Trends in Orthodontics* 2016;6:78 -84.
21
- 22
23 20. * Patterson BM, Dalci O, Darendeliler A, et al. Corticotomies and orthodontic tooth
24
25 movement: A systematic review. *J Oral Maxillofac Surg* 2016;74:453-473.
26
- 27
28 21. Murphy KG, Wilcko MT, Wilcko WM, Ferguson DJ Periodontal Accelerated Osteogenic
29
30 Orthodontics: A Description of the Surgical Technique. *Journal of Oral and*
31
32 *Maxillofacial Surgery* 2009; 67:2160-2166.
33
- 34
35 22. * McBride MD, Campbell PM, Opperman LA, et al. How does the amount of surgical
36
37 insult affect bone around moving teeth? *Am J Orthod Dentofacial Orthop.* 2014;145:S92-
38
39 99.
40
41
42
43
44
45
46
47
48
49
50
51
52
53
54
55
56
57
58
59
60

CAP Paper #4: Surgical consideration of SFOT/PAOO

FIGURES

Fig. 1: Decision tree for SFOT/PAOO.

Fig. 2: Detailed steps of SFOT/PAOO. a) pre-op clinical view; b) pre-op computer analysis of CBCT (note the prevalence of fenestration and dehiscence- dentoalveolar deficiencies); c) surgical view- maxillary view; d) maxilla with corticotomy; e) surgical view- mandibular view; f) mandible with corticotomy; g) bone augmented maxilla with portions covered with collagen barrier membrane; h) closure with ePTFE sutures; i) 1 wk. post-op; j) case completion; and k) post-op computer analysis of CBCT.

Fig. 3: This is a SFOT case with a 10 + yrs. Follow up. a) pre-op view. (note the “corrugated appearance” due to root prominences for the anterior teeth); b) CBCT of the lower anterior segment. (note the lack of supporting alveolar bone); c) post-op CBCT of the same area 14 mos. after SFOT; and d) clinical presentation after 10+ year. The “corrugated appearance” of the facial alveolar bone, seen in the pre-treatment image no longer evident in the post treatment clinical vies, due to bone augmentation. The orthodontic treatment did not result in the appearance of gingival recession.

TABLES

Table 1: Comparison of soft tissue assessment and management by the panelist.

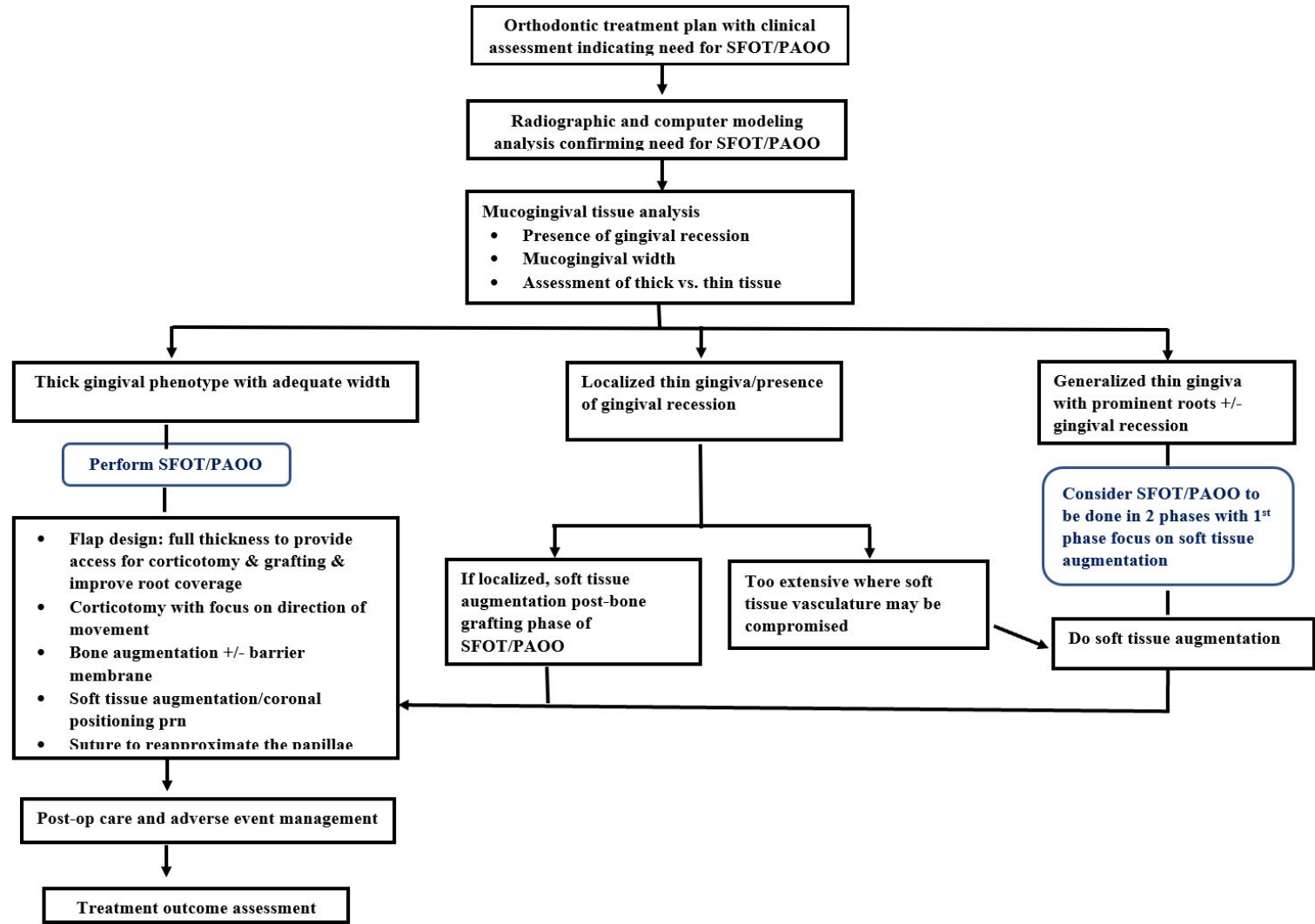
Table 2: Comparison of SFOT/PAOO approach by the panelist.

Table 3: Comparison of post-operative management by the panelist.

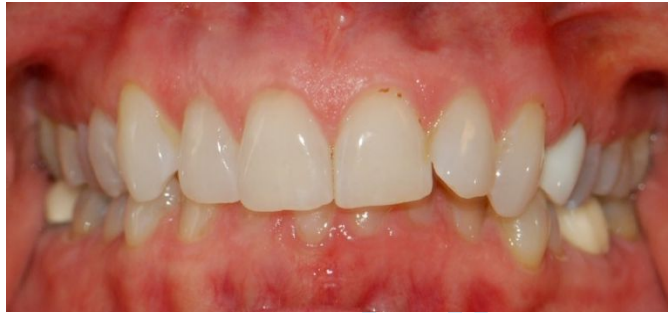FIGURES

Fig. 1

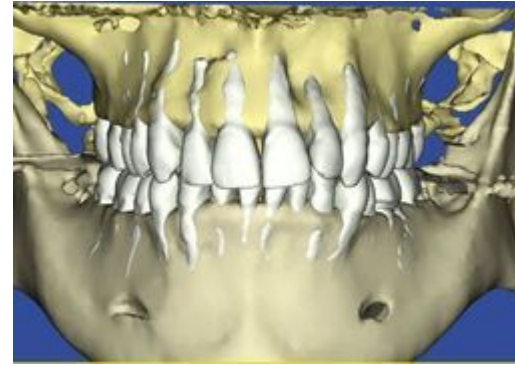
Decision Tree for SFOT/PAOO



1
2
3
4 **Figure 2**
5
6
7



18
19 Fig 2a



20
21
22
23
24
25
26
27
28
29
30
31
32
33
34
35
36
37
38
39
40
41
42
43
44
45
46
47

Fig 2b

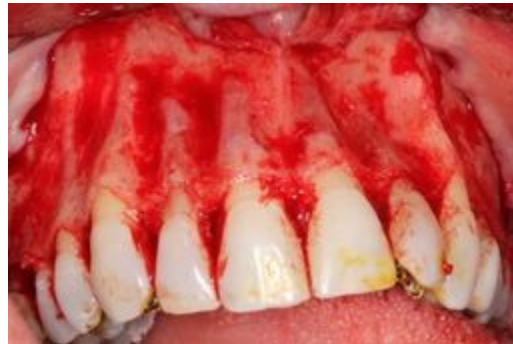

Fig 2c

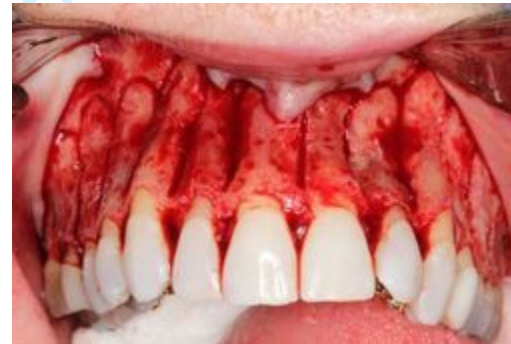

Fig 2d

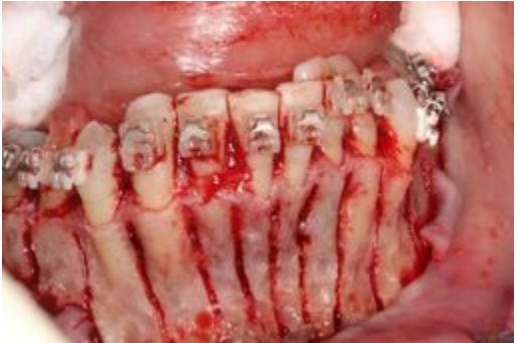
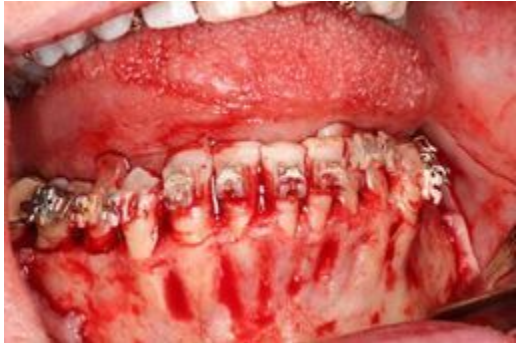
Fig 2e

Fig 2f

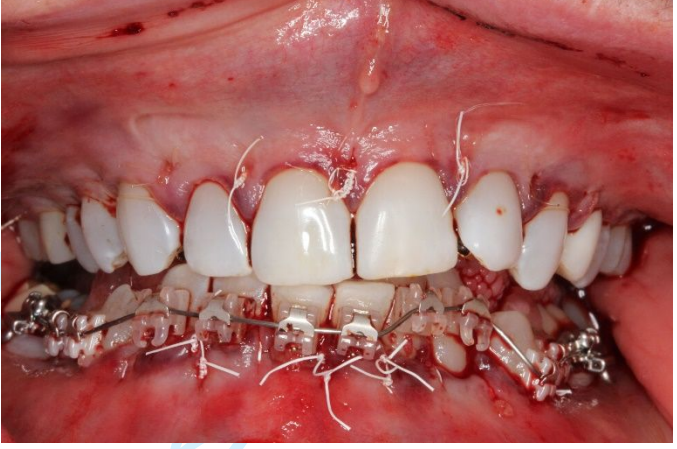
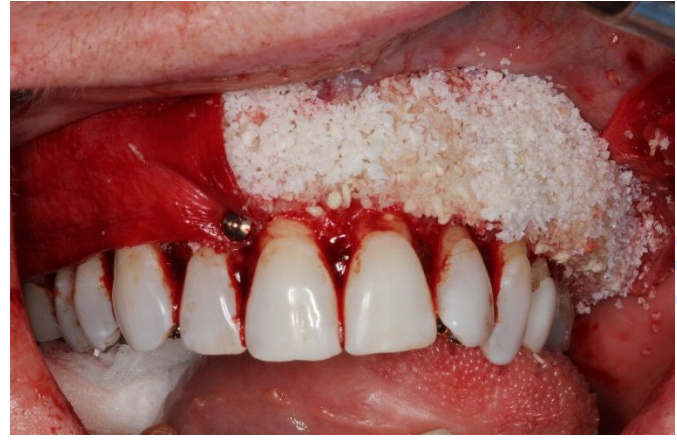

Fig 2g

Fig 2h

1
2
3
4
5
6
7
8
9
10
11
12
13
14
15
16
17
18
19
20
21
22
23
24
25
26
27
28
29
30
31
32
33
34
35
36
37
38
39
40
41
42
43
44
45
46
47

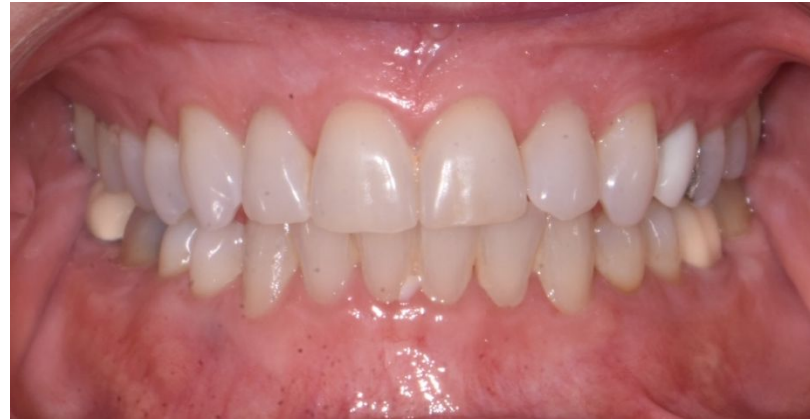
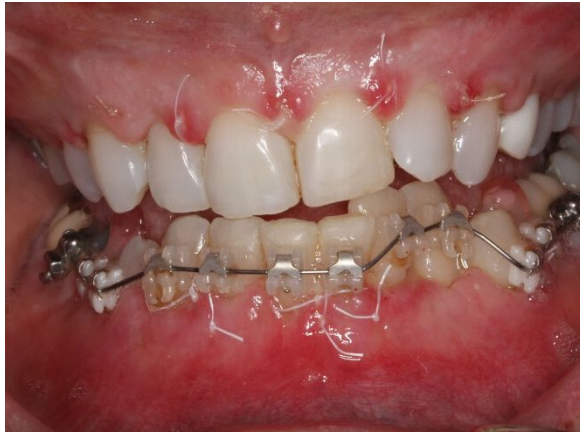
Fig 2i

Fig 2j

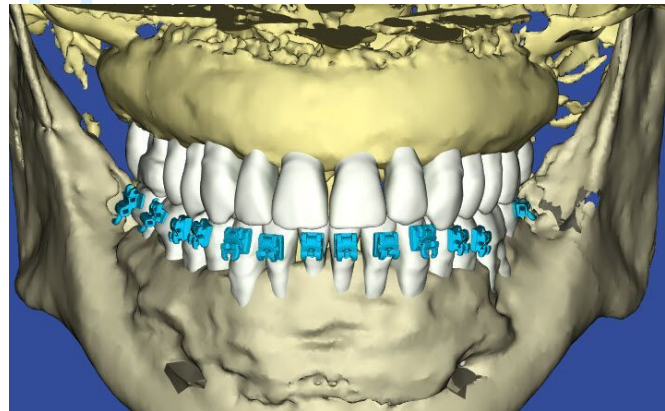


Fig 2k

1
2
3
4
5
6
7
8
9
10
11
12
13
14
15
16
17
18
19
20
21
22
23
24
25
26
27
28
29
30
31
32
33
34
35
36
37
38
39
40
41
42
43
44
45
46
47

Figure 2

1
2
3
4
5
6
7
8
9
10
11
12
13
14
15
16
17
18
19
20
21
22
23
24
25
26
27
28
29
30
31
32
33
34
35
36
37
38
39
40
41
42
43
44
45
46
47

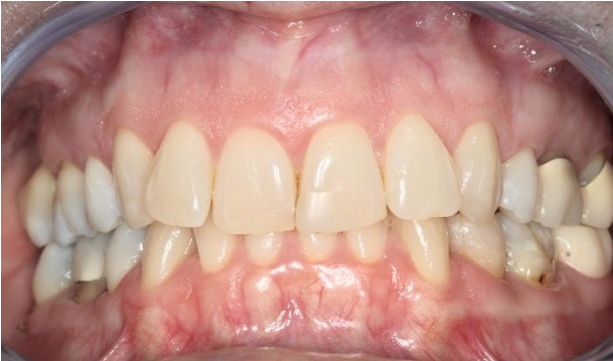

Fig 3a

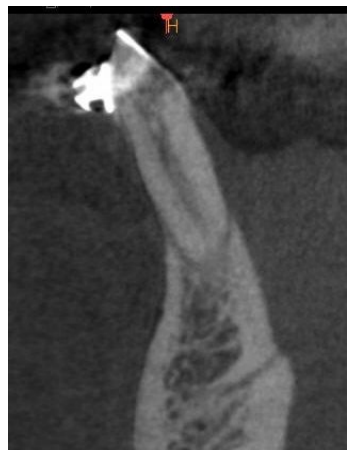

Fig 3b

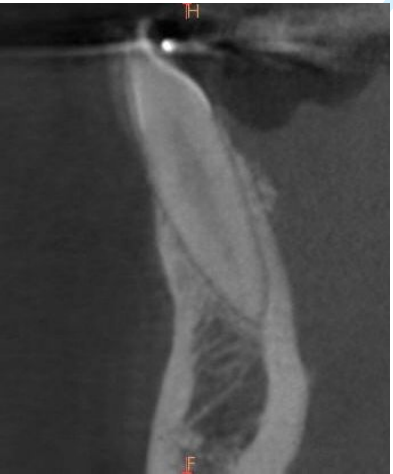

Fig 3c

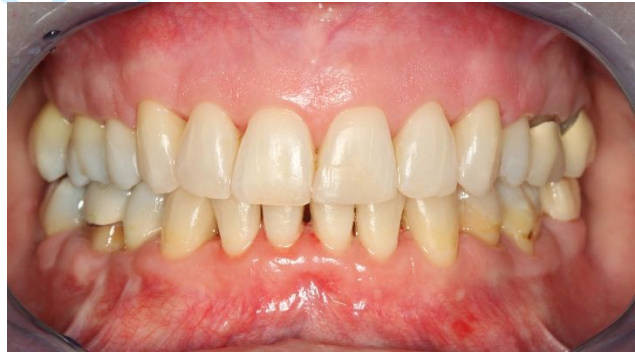

Fig 3d

Table 1: Soft Tissue Assessment and Management

Procedure	Op 1	Op 2	Op 3
<i>Pre-sx consultation with orthodontist</i>	<ul style="list-style-type: none"> ▪ Clinical exam/CBCT ▪ Consultation with orthodontist ▪ Confirm detailing needs timing, and responsible party for TADs and OGS ▪ Pre-operative s/rp, prophyl, and OHI 2 wks. prior to surgery 	<ul style="list-style-type: none"> ▪ Clinical exam/CBCT ▪ Consultation with orthodontist ▪ Confirm detailing needs timing, “roadmap” for treatment and responsible party for TADs and OGS ▪ Pre-surgical hygiene visit: s/rp and prophyl for 1-2 session. with staining and OHI. Stain for plaque index. 	<ul style="list-style-type: none"> ▪ Clinical exam/CBCT ▪ Consultation with orthodontist ▪ Confirm detailing needs timing, and responsible party for TADs and OGS ▪ Pre-surgical hygiene visits within 1 wk. of surgery
<i>Assessment of mucogingival conditions</i>	<ul style="list-style-type: none"> ▪ Mucogingival status is evaluated per 2014 AAP Regeneration Workshop. ▪ Evaluate if there are areas of thin gingival phenotype (as defined by perio probe visibility test)/ with existing gingival recession. ▪ Localized vs. generalized. If generalized, conversation is about 2 phases with soft tissue graft to thicken gingival thickness and a secondary phase for corticotomy and bone grafting procedure 	<ul style="list-style-type: none"> ▪ Mucogingival status is evaluated per 2014 AAP Regeneration Workshop. ▪ Evaluate if there are areas of thin gingival phenotype (as defined by perio probe visibility test)/ with existing gingival recession. ▪ Localized vs. generalized. If generalized, conversation is about 2 phases with soft tissue graft to thicken gingival thickness and a secondary phase for corticotomy and bone grafting procedure 	<ul style="list-style-type: none"> ▪ Mucogingival status is evaluated as per 2014 AAP Regeneration Workshop. ▪ Evaluate if there are areas of thin phenotype (as defined by perio probe visibility test)/with existing gingival recession ▪ If recession, classify as Miller I-IV defect and root coverage predictability ▪ Localized vs. generalized ▪ Many soft tissue considerations may be managed at the time of SFOT. However, aberrant frenum and more extensive recession or phenotype concerns are managed 12 weeks prior to SFOT surgery ▪ NCCL may be managed with bonding prior to SFOT surgery to establish the correct CEJ position
<i>Grafting strategy</i>	<ul style="list-style-type: none"> ▪ SCTG (primary) 	<ul style="list-style-type: none"> • FGG 	<ul style="list-style-type: none"> ▪ Aberrant frenum removed prior to surgery with FGG

	<p>Type of tissue used for gingival grafting: subepithelial connective tissue graft that's harvested from the palate as FGG which is subsequently de-epithelialized with either dermal abrasion with surgical round diamond or ablation with NdYAG laser</p> <ul style="list-style-type: none"> FGG (occasionally for mandibular arch) 	<ul style="list-style-type: none"> Acellular dermal matrix¹ for containment, thicken, for frenum 	<ul style="list-style-type: none"> Soft tissue embellishment with acellular dermal matrix¹ (generalized arch need) or SCTG is more localized
<p>Surgical complications</p>	<ul style="list-style-type: none"> Surgical complications experienced: <ol style="list-style-type: none"> Inadequate soft tissue harvested. Managed by using collagen matrix² or secondary SCTG grafting Inadequate root coverage resolved by coronal repositioning Localized sloughing of the epithelium Delay of corticotomy phase by 3-4 mos while the grafted area revascularize 	<ul style="list-style-type: none"> Areas of gingival sloughing w granulation tissue move up Touch up for inadequate gingival cover- inlay/only FGG Rarely, contamination associated with acellular dermal matrix exposure and used 2x2 to milk suppuration Usually on extremely very thin cases with extensive mucosal tissue so blood supply unable to support Use autogenous FGG Tend to use 2nd rehydration / wash with venous blood 	<p>Complications may include early, moderate or late phase infection usually associated with the bone grafting. The may require I and D or open flap surgery and debridement/graft removal and revision as required</p> <p>Flap dehiscence/perforation leading to mucogingival and/or bone graft problems. Lack of graft containment and poor or failed regenerative result outcome realized.</p> <p>Delayed wound healing with possible worse mucogingival status, pulpal involvement, tooth loss or bone segment sloughage/loss</p> <p>One case of advanced root resorption</p>
<p>Pre-op meds and preparation</p>	<ul style="list-style-type: none"> Clearance for sedation Orthodontic brackets in place 1-2 wks. prior Pre-sx med: Ibuprofen (600mg q6h) start 48hrs prior to surgery CHX at time of surgery for 3min. 	<ul style="list-style-type: none"> Clearance for sedation Orthodontic brackets/aligners in place 2 wks. prior Pre-sx med: if not IV ibuprofen + extra strength acetaminophen + antibiotic 6 Norco prn for pain but seldom used Toradol for IV sedation 	<ul style="list-style-type: none"> Clearance for sedation Orthodontic brackets/aligners in place Pre-sx med: Amoxicillin 2.0g 1 hour op prior or 600mg cleocin 1 hour prior. If general anesthesia, antibiotics are given IV at surgery Pre-sx restorative phase completed

Sedation	<ul style="list-style-type: none"> ▪ Mostly LA ▪ LA +/- some oral sedation w 0.25mg triazolam + 5cc midazolam HCL syrup (2mg/ml) or IV sedation valium – versed combination 	<ul style="list-style-type: none"> ▪ LA +/- sedation administer by nurse anesthetist. 	<ul style="list-style-type: none"> ▪ LA with IV sedation performed by Dr and nurse or dental anesthesiologist. Sometimes in combination with oral sedation (0.25mg Halcion) ▪ General anesthesia via nasal intubation for secure airway by dental anesthesiologist
-----------------	---	--	--

Table 2: SFOT (Corticotomy-Bone Augmentation) Procedure

Procedure	Op 1	Op 2	Op 3
Flap Management	<ul style="list-style-type: none"> ▪ Full thickness flap reflection but need to avoid excessive flap reflection for this allow more dissemination of the graft particles 	<ul style="list-style-type: none"> ▪ Full thickness flap elevation. Flap elevation only for sites where tooth movement is treatment planned. If movement is to buccal then, only facial flap is reflected. If full bodily movement of a tooth is proposed, then both the facial and lingual tissue will be elevated. ▪ Flaps are reflected to approx. 1-2 mm apical to tooth apex to help with containment of graft materials 	<ul style="list-style-type: none"> • Full thickness and broad dissection to identify vital structures/regional anatomy clarity. • Osseous surgery is performed, as needed) for esthetic crown enhancement on the facial aspect so that the dentogingival complex is set in the ideal position for tooth proportion display post-surgery.
Corticotomy procedure	<ul style="list-style-type: none"> ▪ Used piezo to score on the buccal and #1/2 surgical round bur on lingual or to connect piezo cut. It's important to score through the cortical plate which may be ≥ 2.0 mm in thickness 	<ul style="list-style-type: none"> • Corticectomies are completed primarily in the interdental bone septae to a depth of 2 or more mm into medullary bone. • Piezo used exclusively for osseous cuts. • Coronal advance flap as needed for root coverage. 	<ul style="list-style-type: none"> ▪ Interdental cortectomies made with 700,701 or 702 carbide bur in straight handpiece ▪ Apical cut made via semilunar design and 5mm apical to tooth apex ▪ Depth of cortectomies is 3-5mm and intramarrow penetration confirmed


<p>1 2 3 4 5 6 7 8 9 10 11 12 13 14</p>	<ul style="list-style-type: none"> ▪ Tendency to rely on piezo on the buccal and doing a “U” shape design. On the lingual, will do the “U” shape design when possible but in the mandibular canine areas, corticotomy design is often just parallel the root without the apical perpendicular cut if visibility is an issue ▪ No complication / history of tooth / pulpal damage 	<ul style="list-style-type: none"> ▪ No complications 	<ul style="list-style-type: none"> ▪ Osteoplasty (if needed) leading to dentoalveolar decortication performed with round diamond bur in straight handpiece or high speed handpiece. ▪ No complications
<p>15 16 17 18 19 20</p> <p>Management of recession & dehiscence</p>	<ul style="list-style-type: none"> ▪ No noticeable improvement with biologics including stem cell allograft³, rhPDGF⁴, nor enamel matrix derivative⁵. 	<ul style="list-style-type: none"> ▪ Exposed recession areas are treated with EDTA⁶ +s/rp. 	<ul style="list-style-type: none"> ▪ Emdogain is applied to dehiscid or fenestrated root surfaces followed by cancellous allograft
<p>21 22 23 24 25 26 27 28 29 30 31 32 33 34 35 36 37 38 39 40 41 42 43</p> <p>Osseous grafting</p>	<ul style="list-style-type: none"> ▪ FDDBA-superficial porous bone xenograft⁷ ▪ Best results are when resorbable collagen GTR membrane is used for containment. ▪ The critical trick is not to over reflect or the graft particle dispersal control is an issue. 	<ul style="list-style-type: none"> ▪ DFDBA- porous bone xenograft⁷ (in 33%-67% respective ratio) are effective ▪ Place 3-4 mm of graft materials extending the apex of flap reflection ▪ Secures a 4-5mm wide strip of thin Acellular dermal matrix t¹ to lingual aspect of the buccal flap w 5/0 ePTFE (rapid) suture.in a continuous tacking manner such that the coronal edge is 3mm apical to the coronal to the buccal flap 	<ul style="list-style-type: none"> ▪ Corticocancellous allograft (particle size 0.25-1.0mm or layered beyond cancellous allograft or directly onto facial alveolus. Graft is hydrated in PRF ▪ Outer layer of bone graft is via porous bone xenograft⁷ (small particle size). Xenograft is hydrated in PRF. Porous bone xenograft⁷ is the xenograft of choice (Small particle size) ▪ Horizontal bone volume added is proportional to tooth movement needs ▪ Resorbable collagen membrane is trimmed and adapted over reconstructed area and fixated to place via tacks. 40 x 50mm collagen

	<ul style="list-style-type: none"> ▪ Unsuccessful approaches: Previous use of DFDBA, FDBA, and stem cell allograft.³ Similar / less effective compare to present protocol. 	<ul style="list-style-type: none"> ▪ Unsuccessful approaches: Minimal long-term success with PRF and has discontinued Have tried DFDBA-FDBA (50-50%) a little less volume gain 	<p>matrix membrane⁸ is the membrane of choice (one per arch)</p> <ul style="list-style-type: none"> ▪ Unsuccessful approaches: Previous strategies tried and abandoned: <ul style="list-style-type: none"> - collatape as membrane - no membrane - use of bone putty
Flap Management	<ul style="list-style-type: none"> ▪ Use 5-0 chromic cut in a continuous fashion to realign the papillae and used as stay suture. ▪ Use 5-0 ePTFE simple suture to stabilize each papilla area and horizontal mattress prn starting on the lingual aspect to suspend the buccal flap at the appropriate height 	<ul style="list-style-type: none"> • Secure flap both horizontally and vertically w 5-0 ePTFE mattress sutures 	<ul style="list-style-type: none"> ▪ ePTFE (if performing advanced GBR in an edentulous area) or 5-0 Monocryl sutures are used in the posterior with a sling design ▪ Anterior sextant is sutured via 5-0 or 6-0 polypropylene via horizontal mattress design and monocryl via everting mattress at the interdental papillary areas to

Table 3: Post-operative Care

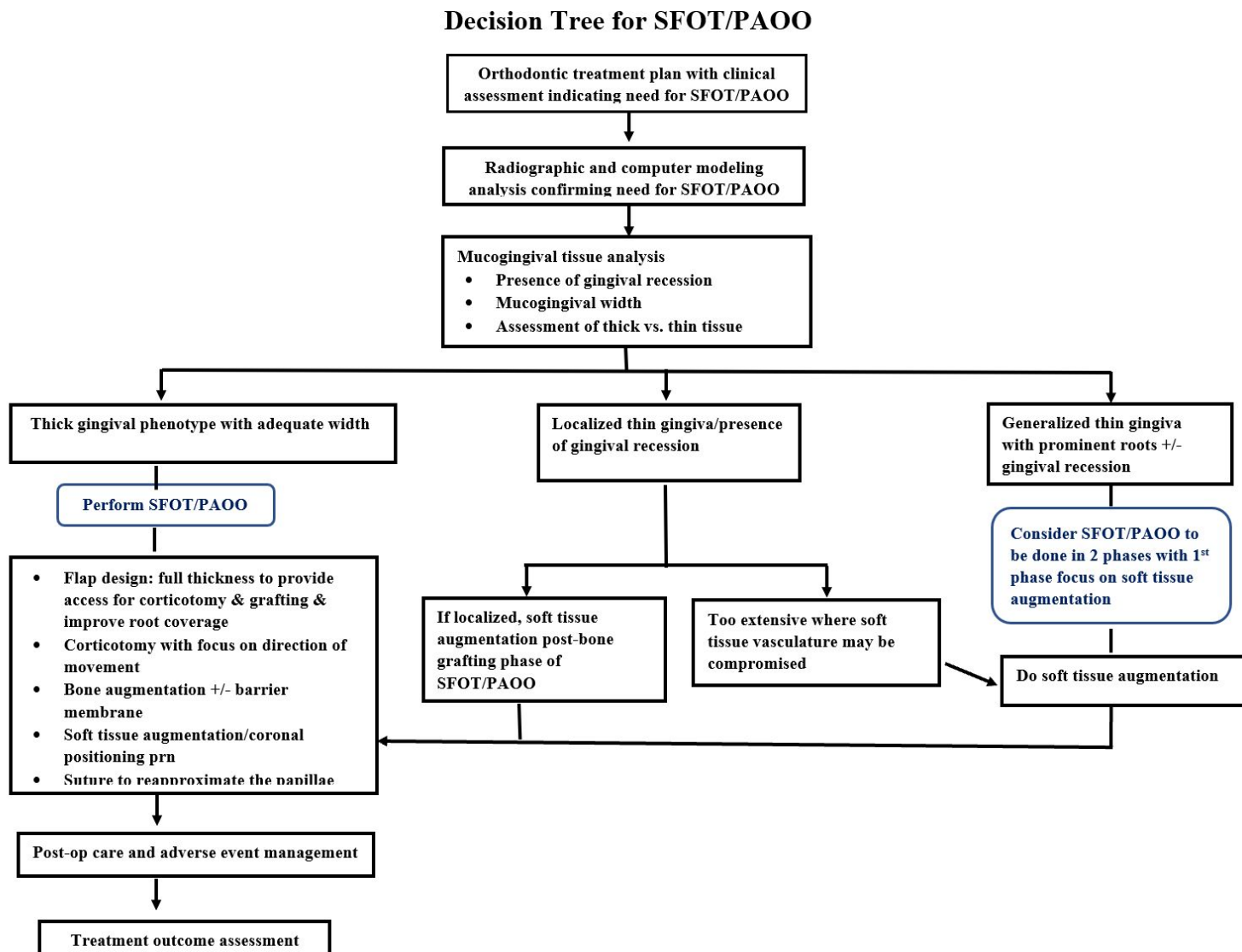
Procedure	Op 1	Op 2	Op 3
PO-Surgical management	<ul style="list-style-type: none"> ▪ Surgical complication consistent with extensive soft tissue grafting that consist of marginal sloughing/necrosis, incomplete root coverage for short termed (\leq 3mos) ▪ Secondary soft tissue augmentation procedure may be necessary 6 mos. out 	<ul style="list-style-type: none"> • Amoxicillin (500g) qid x 5 d; • Ibuprofen 600mq6h x 5 d • CHX rinses tid x 3 wks. • Norco (6 tab prn. Note: very few patients filled this script) • Sutures removed 2-3 wks. PO • OH assessment at 6wks PO with supra-gingival polishing • SPT at 3 mos. and alternate with GPs office 	<ul style="list-style-type: none"> ▪ Post-surgical visits occur at 1-2 weeks, 4 weeks, 8-12 weeks and 6 months. Sutures removed at 4 (posterior) or 8 weeks (polypropylene) ▪ At 4 weeks, 8 weeks and 6 months, full mouth supragingival debridement is performed. 3-4 months are allowed for RAP phase tooth movement

	<ul style="list-style-type: none"> ▪ PO check at wk. 1, 2, 4, 8, 12 and then quarterly thereafter. ▪ CBCT scan 1 yr. out and at end of treatment (2-3yrs po) 	<ul style="list-style-type: none"> • CBCT scan 12 mos. after • Seldom have complication but can be associated with of small localized area of sloughing which area managed with gentle debridement with supplemental CHX 	<ul style="list-style-type: none"> ▪ Evaluate for revision mucogingival surgery as needed ▪ CBCT post op at 6 months
<i>Orthodontic management</i>	<ul style="list-style-type: none"> ▪ Arch wire is placed and activated right after 1 wk. post-op ▪ Orthodontist management of movement every 2-3 wks. for first 3 mos. then once a month ▪ Standard orthodontic analysis ▪ May involve moving to a second phase of orthognathic surgery to complete ideal results ▪ Periodontal maintenance q3-4 mos. until debanding. 	<ul style="list-style-type: none"> • Arch wire placed at the end of surgery 	<ul style="list-style-type: none"> ▪ Archwires or aligned activated to take advantage of RAP at 1-2 weeks post SFOT surgery ▪ Heavy archwires are replaced every 2 weeks ▪ Aligners are changed every 3 days ▪ Standard orthodontic analysis and outcome goals with expansion and non-extraction context preferred ▪ Orthodontic decompensation planned to either manage malocclusion entirely or set case up for orthognathic surgery ▪ Post SFOT restorative completed to set up tooth proportions and anatomy more optimally prior to orthognathic surgery ▪ Orthognathic surgery as needed ▪ Repeat WatchPAT analysis at treatment outcome to assess for UARS or OSA changes ▪ Prosthetic phase completion, if needed ▪ Periodontal maintenance q4-6 months

 Highlighted procedures are common therapeutic approaches shared by all

Abbreviations: OGS orthognathic surgery; TAD temporary anchorage devices
 1. Alloderm®; 2. Mucograft® ; 3. Osteocel®; 4. PDGF®; 5. Emdogain®; 6. PrefGel®; 7. BioOss®; 8 BioGide®

Fig. 1

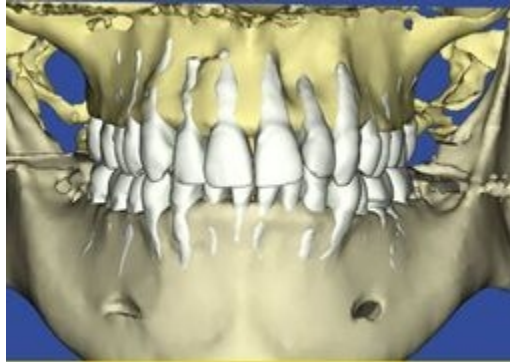


1
2
3
4
5
6
7
8
9
10
11
12
13
14
15
16
17
18
19
20
21
22
23
24
25
26
27
28
29
30
31
32
33
34
35
36
37
38
39
40
41
42
43
44
45
46
47
48
49
50
51
52
53
54
55
56
57
58
59
60

Colleen McLaughlin, 60y 10m, 10/14/16
Dr. Jwei M. Huang, Gold Coast Orthodontics

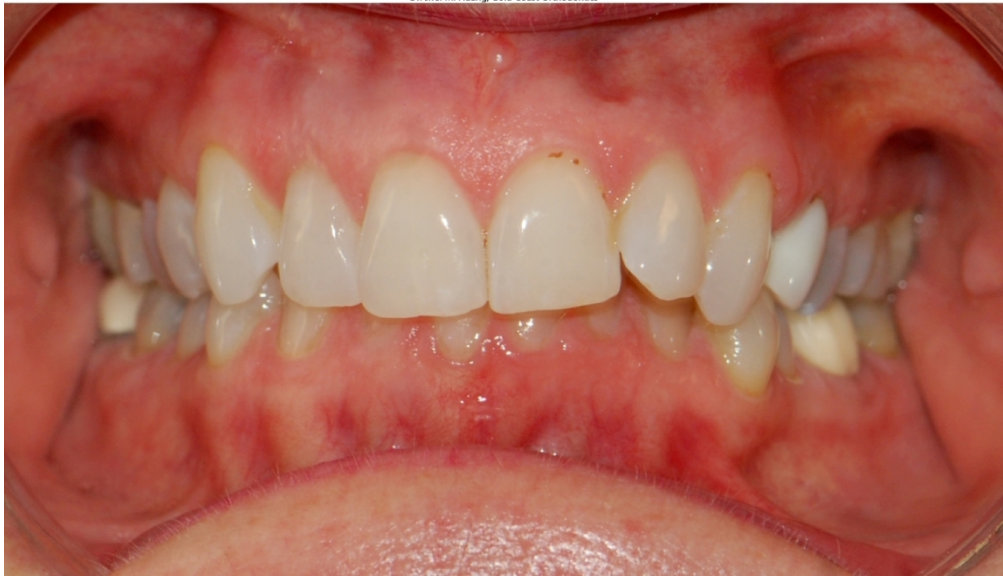

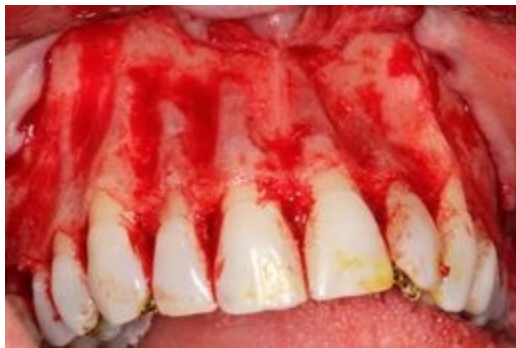Fig. 2: Detailed steps of SFOT/PAOO. a) pre-op clinical view;
127x76mm (300 x 300 DPI)



b) pre-op computer analysis of CBCT (note the prevalence of fenestration and dehiscence- dentoalveolar deficiencies);

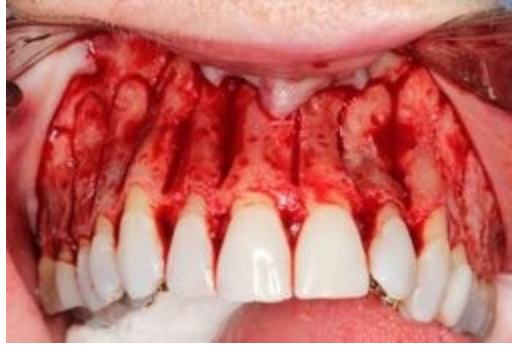90x63mm (72 x 72 DPI)

1
2
3
4
5
6
7
8
9
10
11
12
13
14
15
16
17
18
19
20
21
22
23
24
25
26
27
28
29
30
31
32
33
34
35
36
37
38
39
40
41
42
43
44
45
46
47
48
49
50
51
52
53
54
55
56
57
58
59
60



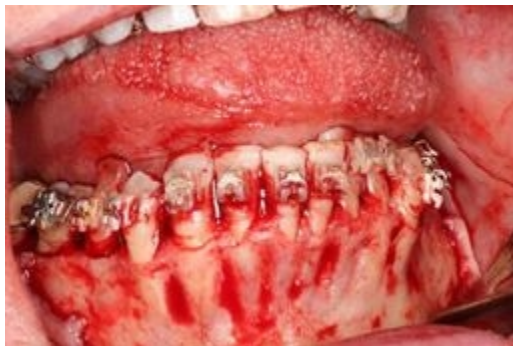c) surgical view- maxillary view;
90x60mm (72 x 72 DPI)

1
2
3
4
5
6
7
8
9
10
11
12
13
14
15
16
17
18
19
20
21
22
23
24
25
26
27
28
29
30
31
32
33
34
35
36
37
38
39
40
41
42
43
44
45
46
47
48
49
50
51
52
53
54
55
56
57
58
59
60



d) maxilla with corticotomy;
90x60mm (72 x 72 DPI)

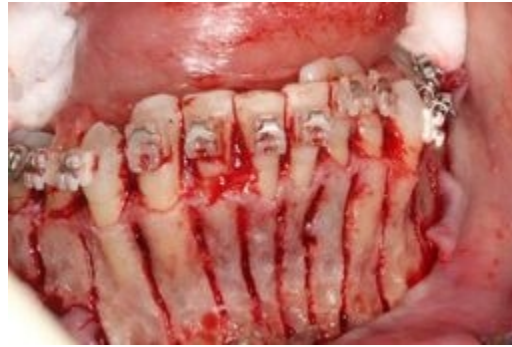1
2
3
4
5
6
7
8
9
10
11
12
13
14
15
16
17
18
19
20
21
22
23
24
25
26
27
28
29
30
31
32
33
34
35
36
37
38
39
40
41
42
43
44
45
46
47
48
49
50
51
52
53
54
55
56
57
58
59
60



e) surgical view- mandibular view;

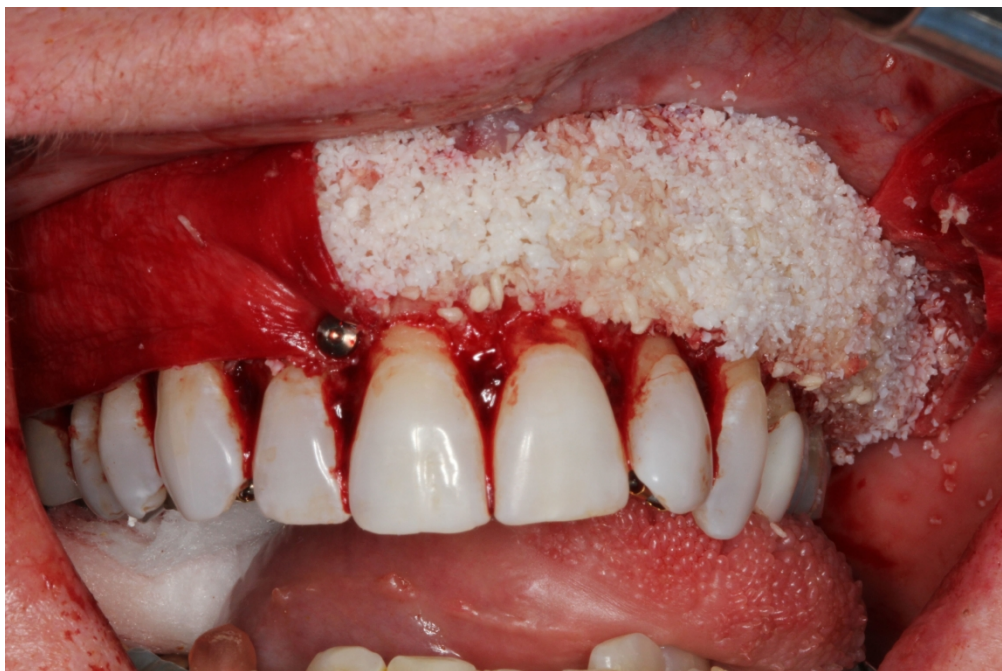90x60mm (72 x 72 DPI)

1
2
3
4
5
6
7
8
9
10
11
12
13
14
15
16
17
18
19
20
21
22
23
24
25
26
27
28
29
30
31
32
33
34
35
36
37
38
39
40
41
42
43
44
45
46
47
48
49
50
51
52
53
54
55
56
57
58
59
60

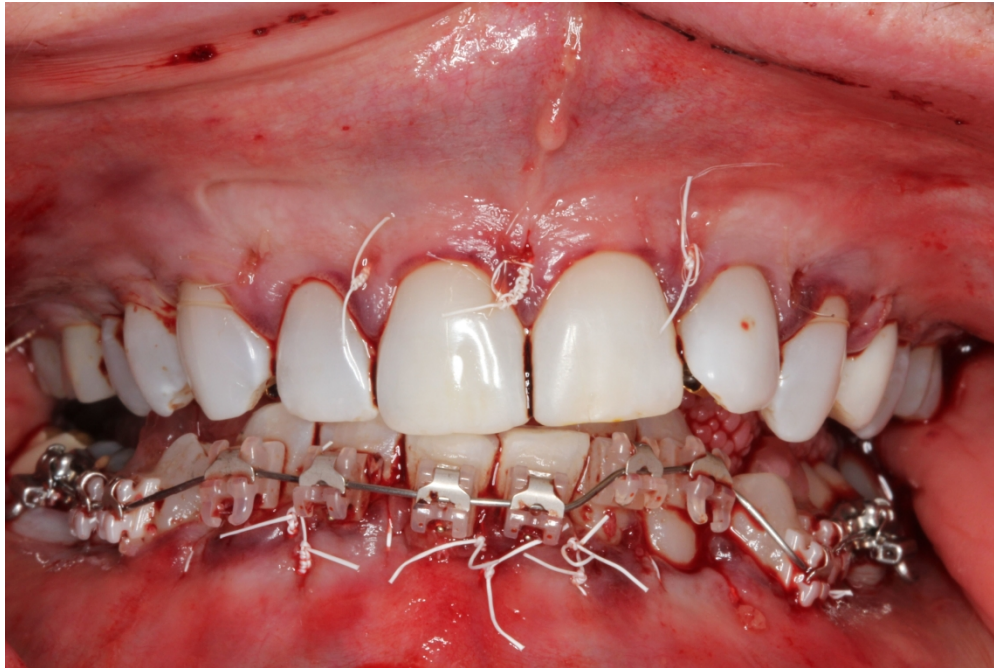

f) mandible with corticotomy;
90x60mm (72 x 72 DPI)

1
2
3
4
5
6
7
8
9
10
11
12
13
14
15
16
17
18
19
20
21
22
23
24
25
26
27
28
29
30
31
32
33
34
35
36
37
38
39
40
41
42
43
44
45
46
47
48
49
50
51
52
53
54
55
56
57
58
59
60



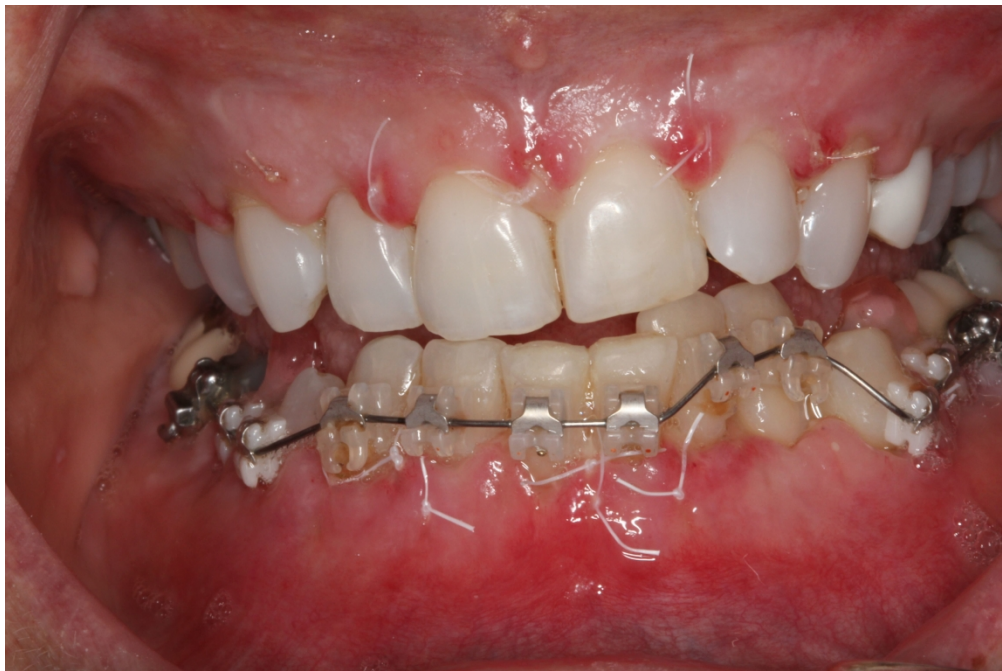g) bone augmented maxilla with portions covered with collagen barrier membrane;
1828x1219mm (72 x 72 DPI)



h) closure with ePTFE sutures;

1828x1219mm (72 x 72 DPI)

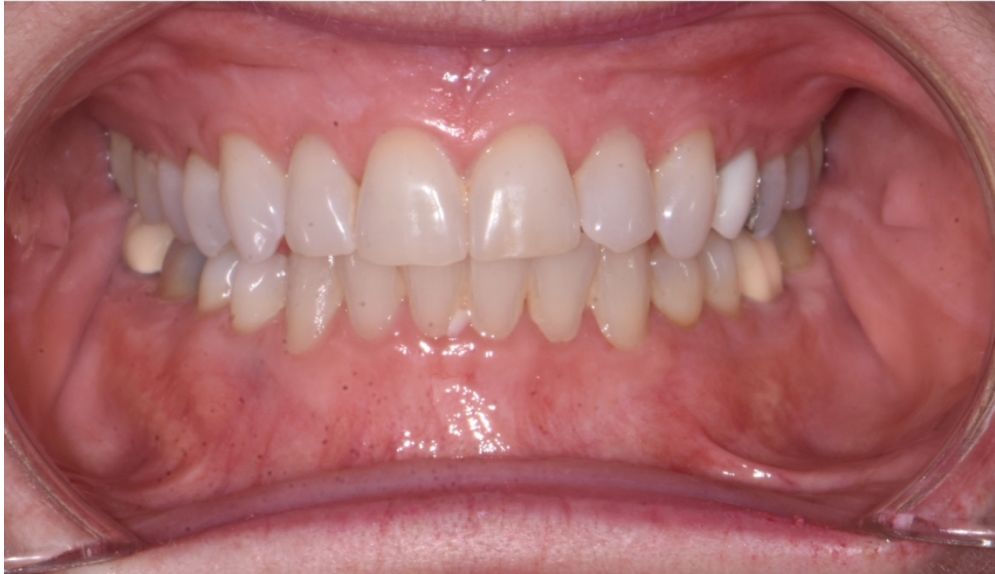1
2
3
4
5
6
7
8
9
10
11
12
13
14
15
16
17
18
19
20
21
22
23
24
25
26
27
28
29
30
31
32
33
34
35
36
37
38
39
40
41
42
43
44
45
46
47
48
49
50
51
52
53
54
55
56
57
58
59
60



i) 1 wk. post-op; k) case completion;
1828x1219mm (72 x 72 DPI)

1
2
3
4
5
6
7
8
9
10
11
12
13
14
15
16
17
18
19
20
21
22
23
24
25
26
27
28
29
30
31
32
33
34
35
36
37
38
39
40
41
42
43
44
45
46
47
48
49
50
51
52
53
54
55
56
57
58
59
60

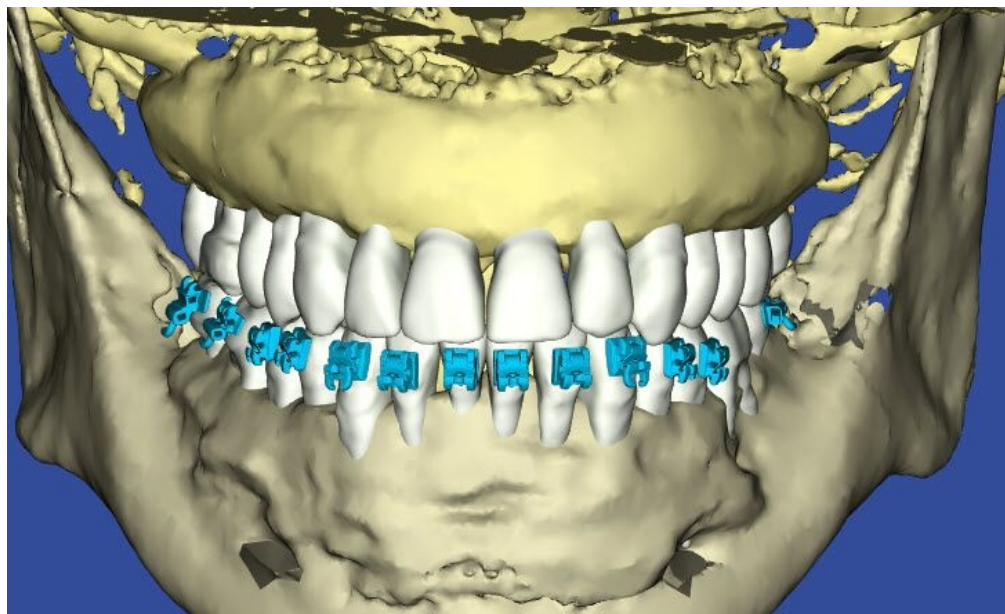
Colleen McLaughlin, 62y 4m, 05/07/18
Dr. Iwei M. Huang, Gold Coast Orthodontics



j) case completion;

127x76mm (300 x 300 DPI)

1
2
3
4
5
6
7
8
9
10
11
12
13
14
15
16
17
18
19
20
21
22
23
24
25
26
27
28
29
30
31
32
33
34
35
36
37
38
39
40
41
42
43
44
45
46
47
48
49
50
51
52
53
54
55
56
57
58
59
60



and k) post-op computer analysis of CBCT.

255x156mm (72 x 72 DPI)

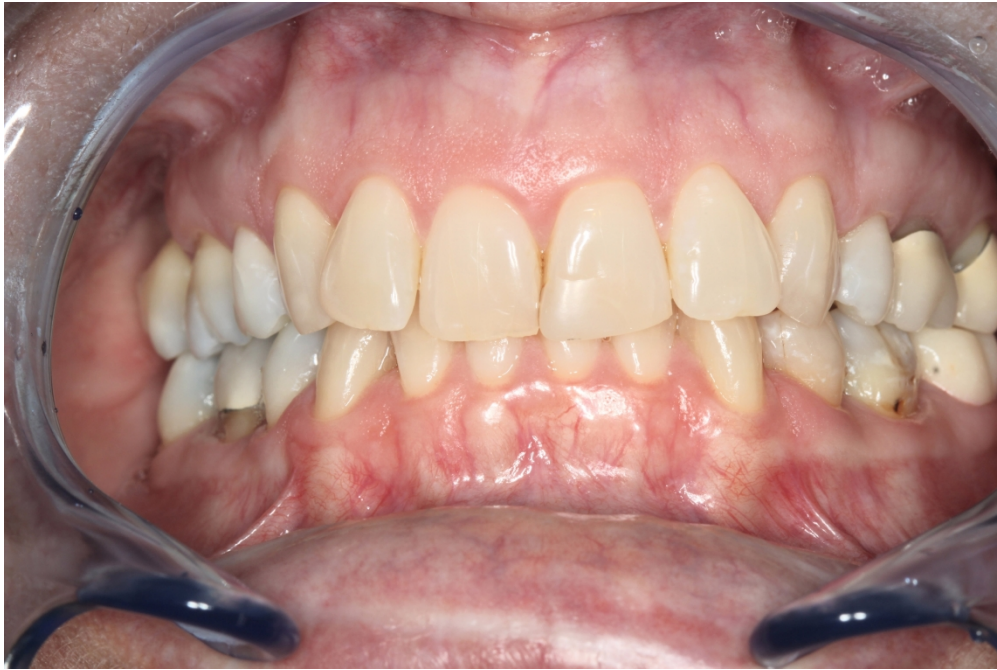
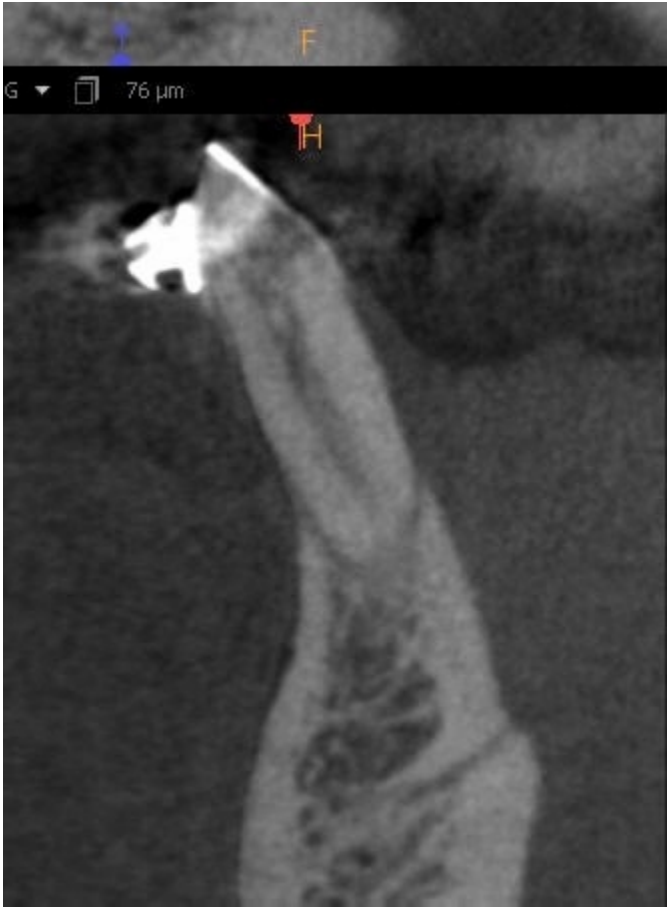
Fig. 3: This is a SFOT case with a 10 + yrs. Follow up. a) pre-op view. (note the "corrugated appearance" due to root prominences for the anterior teeth);

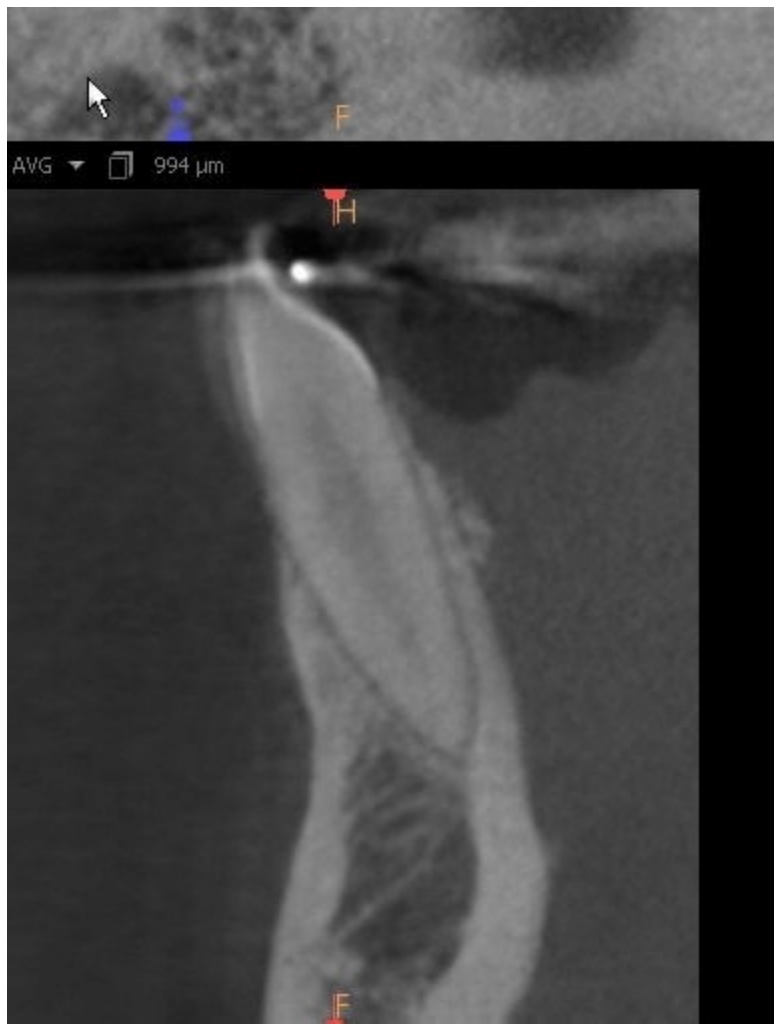1676x1117mm (72 x 72 DPI)

1
2
3
4
5
6
7
8
9
10
11
12
13
14
15
16
17
18
19
20
21
22
23
24
25
26
27
28
29
30
31
32
33
34
35
36
37
38
39
40
41
42
43
44
45
46
47
48
49
50
51
52
53
54
55
56
57
58
59
60



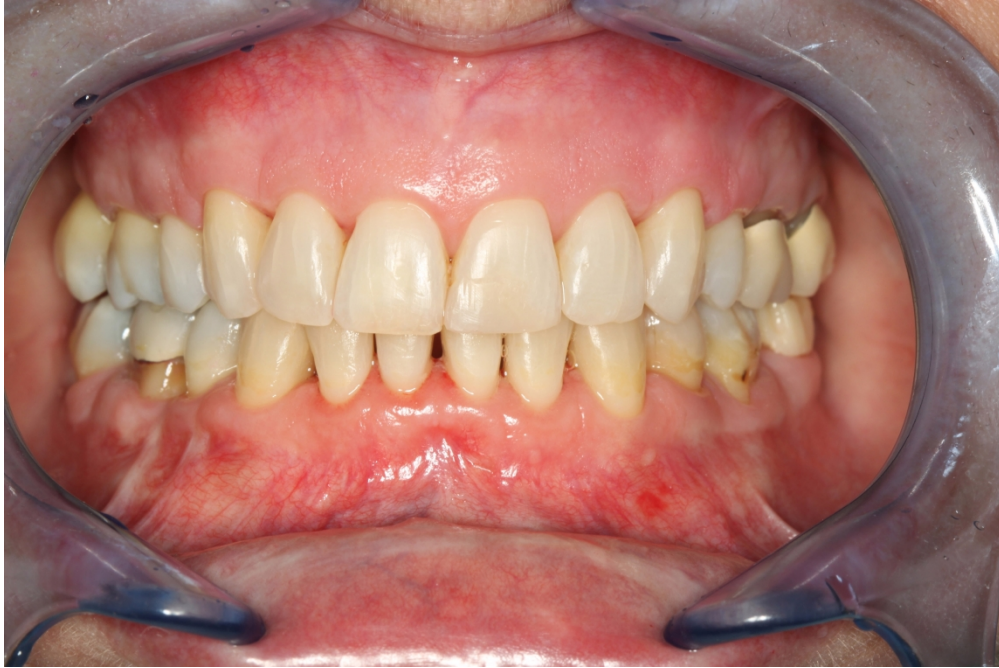b) CBCT of the lower anterior segment. (note the lack of supporting alveolar bone);
117x159mm (72 x 72 DPI)

1
2
3
4
5
6
7
8
9
10
11
12
13
14
15
16
17
18
19
20
21
22
23
24
25
26
27
28
29
30
31
32
33
34
35
36
37
38
39
40
41
42
43
44
45
46
47
48
49
50
51
52
53
54
55
56
57
58
59
60



c) post-op CBCT of the same area 14 mos. after SFOT;

135x179mm (72 x 72 DPI)



and d) clinical presentation after 10+ year. The "corrugated appearance" of the facial alveolar bone, seen in the pre-treatment image no longer evident in the post treatment clinical vies, due to bone augmentation. The orthodontic treatment did not result in the appearance of gingival recession.

1676x1117mm (72 x 72 DPI)